

Blepharokeratoconjunctivitis of childhood

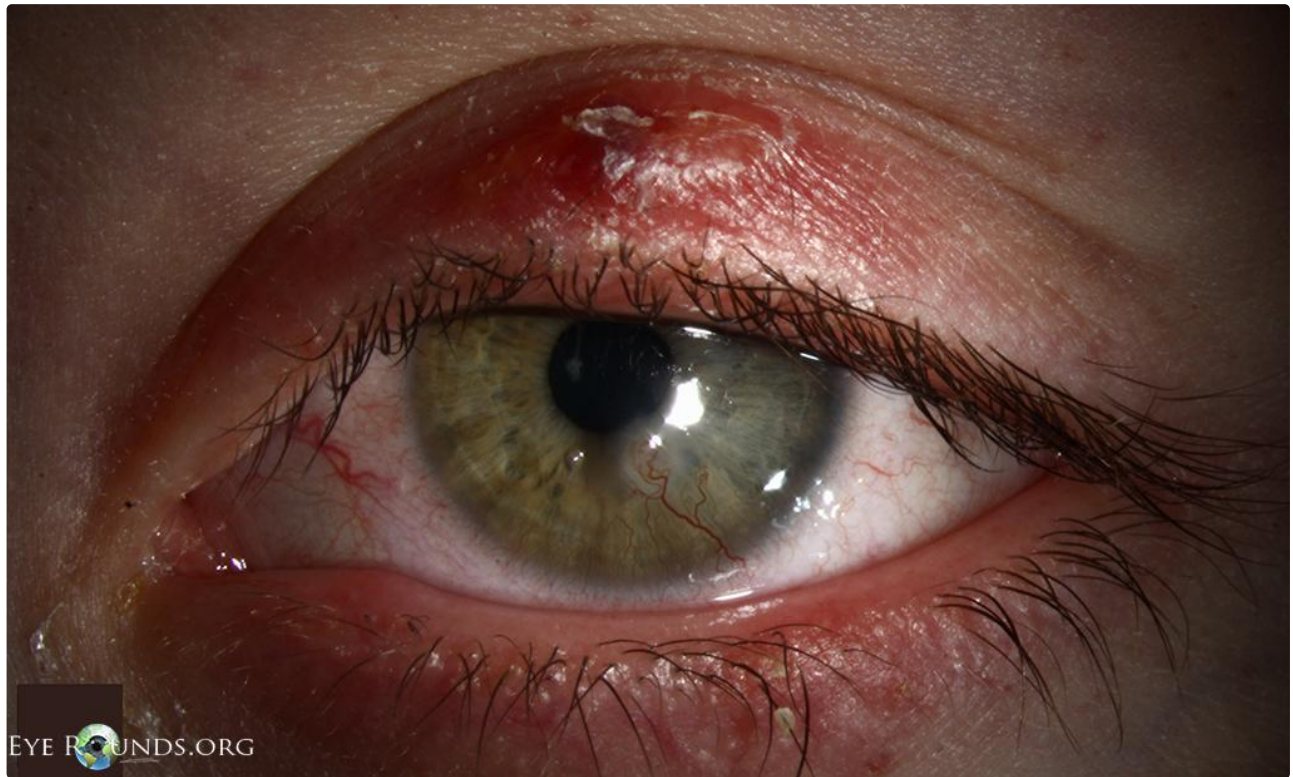Category(ies): Cornea, Pediatrics, External Disease

Contributor: [Justin Risma, MD](#)

Photographer: Stefani Karakas, CRA

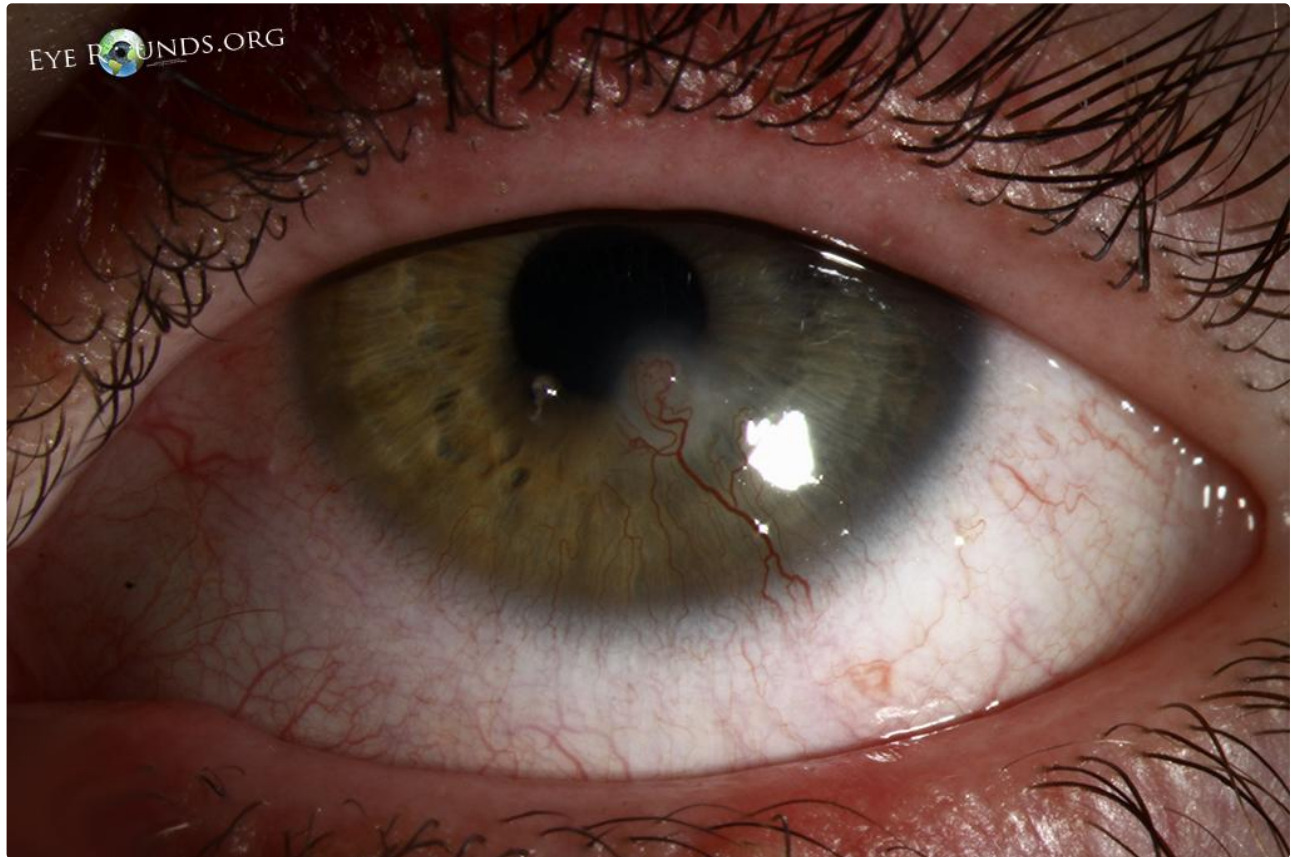


Blepharokeratoconjunctivitis of childhood is characterized by blepharitis with recurrent episodes of conjunctivitis and keratopathy, including punctate erosions, phlyctenules, marginal keratitis, and ulceration. Treatment may include warm compresses, lid scrubs, topical antibiotics, topical corticosteroids, and systemic antibiotics. The disease rarely progresses after age 8. This 7-year-old female has a history of recurrent styes, corneal phlyctenules, and filamentary keratitis, as demonstrated in these photos.



[Enlarge](#)

[Download](#)



[Enlarge](#)

[Download](#)

References:

1. Viswalingam M, Rauz S, Morlet N, Dart JK. [Blepharokeratoconjunctivitis in children: diagnosis and treatment](#). Br J Ophthalmol. 2005 Apr;89(4):400-3. PubMed PMID: 15774912; PubMed Central PMCID: PMC1772603

Image Permissions:



Ophthalmic Atlas Images by [EyeRounds.org](#), [The University of Iowa](#) are licensed under a [Creative Commons Attribution-NonCommercial-NoDerivs 3.0 Unported License](#).

Address

University of Iowa
Roy J. and Lucille A. Carver College
of Medicine

Legal

Copyright © 2019 The University of
Iowa. All Rights Reserved
Report an issue with this page

Related Links

Cataract Surgery for Greenhorns
EyeTransillumination
Gonioscopy.org

EyeRounds Social Media

Follow

Department of Ophthalmology and
Visual Sciences
200 Hawkins Drive
Iowa City, IA 52242

[Support Us](#)

[Web Privacy Policy](#) |
[Nondiscrimination Statement](#)

[Iowa Glaucoma Curriculum](#)
[Iowa Wet Lab](#)
[Patient Information](#)
[Stone Rounds](#)
[The Best Hits Bookshelf](#)



[Receive notification of new cases,
sign up here](#)
[Contact Us](#)
[Submit a Suggestion](#)